

CERVICITIS CHRONIC ET CAUSA TUBERCULOUS: A CASE REPORT

Maurizka Juwita Siregar¹, Taufik Hidayat Djais², Enny Nugraheni³

¹ General Practitioner, M. Yunus General Hospital, Bengkulu, Indonesia

² Departement of Obstetric and Gynaecology – Subspecialist Oncology, M. Yunus General Hospital, Bengkulu, Indonesia

³ Faculty of Medicine and Health Sciences, Bengkulu University, Bengkulu, Indonesia

ARTICLE INFO

Corresponding author :

Maurizka Juwita Siregar
General Practitioner, M.
Yunus General Hospital,
Bengkulu

Email:

maurizkajuwita14@gmail.com

Kata kunci:

Servisitit Tuberkulosis
Tuberkulosis Genital
Servisitit Kronis
Biopsi Serviks
Terapi Anti-Tuberkulosis

Keywords:

Tuberculous Cervicitis
Genital Tuberculosis
Chronic Cervicitis
Cervical Biopsy
Anti-Tuberculosis Therapy

Original submission:

June 15, 2025

Accepted:

July 8, 2025

Published:

September 20, 2025

ABSTRAK

Servisitit tuberkulosis adalah manifestasi langka dari tuberkulosis genital yang sering menyerupai kanker serviks karena kemiripan gejala klinis, seperti perdarahan vagina tidak normal dan keputihan. Deteksi dini sangat penting untuk mencegah diagnosis dan terapi yang tidak tepat. Wanita 37 tahun mengalami perdarahan vagina enam bulan, perdarahan pascakoitus, dan keputihan yang baru dirasakan. Pemeriksaan fisik menunjukkan adanya lesi serviks yang tidak teratur, namun hasil laboratorium dan pencitraan tidak memberikan hasil yang konklusif. Biopsi konisasi menunjukkan adanya peradangan granulomatosa dengan nekrosis kaseosa, mengonfirmasi servisitit tuberkulosis. Pewarnaan basil tahan asam negatif. Pasien diterapi dengan obat antituberkulosis standar, yang menghasilkan perbaikan gejala dan kondisi klinis. Servisitit tuberkulosis sering luput terdiagnosis karena jarang dan gejalanya menyerupai keganasan. Diagnosis bergantung pada histopatologi, karena konfirmasi mikrobiologis sulit. Pengobatan antituberkulosis yang cepat mencegah komplikasi serius. Intervensi bedah mungkin diperlukan untuk diagnosis maupun terapi.

Kesimpulan : Servisitit tuberkulosis harus dipertimbangkan pada kasus servisitit kronis, terutama di daerah endemis. Diagnosis dan terapi yang tepat waktu mendukung prognosis baik dan mencegah tindakan invasif yang tidak perlu.

ABSTRACT

Cervicitis Chronic Et Causa Tuberculosis: A Case Report. Tuberculous cervicitis is a rare form of genital tuberculosis that often mimics cervical cancer due to similar symptoms, such as abnormal vaginal bleeding and vaginal discharge. Early detection is crucial to prevent misdiagnosis and mistreatment. A 37-year-old woman presented with six months of vaginal bleeding, postcoital bleeding, and recent vaginal discharge. Physical examination revealed an irregular cervical lesion, but laboratory and imaging findings were inconclusive. A conization biopsy revealed granulomatous inflammation with caseous necrosis, confirming tuberculous cervicitis. Acid-fast bacillus staining was negative. The patient was treated with standard antituberculous regimen, resulting in symptom resolution and clinical improvement. Tuberculous cervicitis is often missed due to its rarity and malignancy-like symptoms. Diagnosis relies on histopathology, as microbiological confirmation is difficult. Prompt antituberculous treatment prevents serious complications. Surgical intervention may be necessary for both diagnosis and treatment. Conclusion: Tuberculous cervicitis should be considered in cases of chronic cervicitis, especially in endemic areas. Timely diagnosis and treatment promote a good prognosis and prevent unnecessary invasive procedures.

INTRODUCTION

Cervicitis, an inflammation of the uterine cervix, is a frequently encountered gynecological condition.¹ Various factors, including infectious agents and non-infectious triggers, can cause it. Common infectious causes include sexually transmitted infections such as *Chlamydia trachomatis*, *Neisseria gonorrhoeae*, *Trichomonas vaginalis*, and Herpes Simplex Virus (HSV) and bacteria associated with bacterial vaginosis. Non-infectious causes can encompass mechanical or chemical irritation, trauma, or allergic reactions.¹ While specific prevalence data for general cervicitis can vary widely by population and diagnostic criteria, it is recognized as a standard issue globally.² In Asian countries, infectious cervicitis contributes significantly to gynecological morbidity³. In Indonesia, while specific comprehensive data on all-cause cervicitis is still developing, infections of the lower genital tract are a known health concern.⁴

Among the various etiological agents, *Mycobacterium tuberculosis* can cause a specific form of chronic cervicitis known as tuberculous cervicitis. This condition is distinct from common cervicitis in several ways. Common cervicitis typically results from the aforementioned pathogens or non-infectious causes, leading to acute or nonspecific chronic inflammation, often diagnosed by direct pathogen detection or clinical presentation.¹ In contrast, tuberculous cervicitis is a rare form of extrapulmonary tuberculosis characterized by chronic granulomatous inflammation. It usually occurs secondary to tuberculosis elsewhere in the body, with bacilli reaching the cervix typically via hematogenous spread from a primary pulmonary or abdominal focus. However, lymphatic spread or direct extension is also possible.^{5,6} Histopathologically, tuberculous cervicitis is distinguished by epithelioid granulomas, Langhans giant cells, and often caseous necrosis, features not seen in common cervicitis. Tuberculous cervicitis accounts for a very small percentage of all tuberculosis cases, reportedly between 0.1% to 0.65%, and represents about 5% of female genital tract tuberculosis cases globally.⁷ While rare, its incidence is higher in regions endemic for tuberculosis. Indonesia, being a country with a high TB burden,⁸ sees genital tuberculosis (including cervical involvement as a smaller subset) in approximately 1% to 7% of women investigated for infertility or chronic pelvic inflammatory disease.^{4,8,9}

The urgency to diagnose tuberculous cervicitis accurately cannot be overstated. One of the primary reasons for this urgency is its propensity to clinically and macroscopically mimic cervical cancer, presenting with nonspecific symptoms such as abnormal vaginal bleeding, postcoital bleeding, and vaginal discharge. This resemblance can lead to diagnostic dilemmas, potential misdiagnosis, and consequently, inappropriate or delayed treatment, including unnecessary oncological interventions. Early and accurate diagnosis is crucial for initiating antituberculous therapy (ATT). Prompt treatment is essential not only for curing the infection but also for preventing severe and often irreversible complications, such as infertility, chronic pelvic pain, and the potential for further spread of the infection. Furthermore, diagnosis can be challenging as acid-fast bacilli are often scarce in cervical lesions (paucibacillary nature), leading to negative results on direct staining and cultural difficulties. Therefore, a high index of suspicion, particularly in patients from TB-endemic areas or those with risk factors, coupled with careful histopathological examination of cervical biopsies.^{7,10}

CASE REPORT

Patient Demographics and History

We report a case of a 37-year-old woman, Mrs. R, residing in Bengkulu, who presented to the gynecology outpatient clinic with complaints of persistent vaginal pain and bleeding for six months.

The bleeding was notably exacerbated after sexual intercourse. Additionally, she reported vaginal discharge for one month, described as white, non-foul smelling, and non-pruritic. She denied systemic symptoms such as fever, cough, or weight loss.

Her past medical history was significant for hypertension, managed with amlodipine 10 mg daily. There was no history of diabetes mellitus or asthma. Family history revealed hypertension in her mother but no known tuberculosis. She was in her second marriage for two years and had two previous pregnancies, resulting in two healthy female children being born at term.

Menstrual history was unremarkable, with regular 28-day cycles lasting 4-5 days, moderate flow, and menarche at age 15. She had been using injectable contraceptives every three months for three years without complications.

Clinical Presentation and Examination

The patient was alert and in good general condition during the physical exam. Vital signs were stable with blood pressure 120/70 mmHg, pulse 90 beats per minute, respiratory rate 20 breaths per minute, temperature 36.5°C, and oxygen saturation 99% on room air. Body mass index was within normal limits.

General physical examination revealed no pallor, jaundice, or lymphadenopathy. Respiratory and cardiovascular examinations were unremarkable. Abdominal examination showed no tenderness or organomegaly.

A gynecological examination revealed normal external genitalia. Speculum examination showed a cervix with yellowish leukorrhea but no visible ulceration, erosion, or polypoid lesions. The portio was not livid, and the external os was closed (Figure 1). The bimanual examination was unremarkable, with no adnexal masses or tenderness.

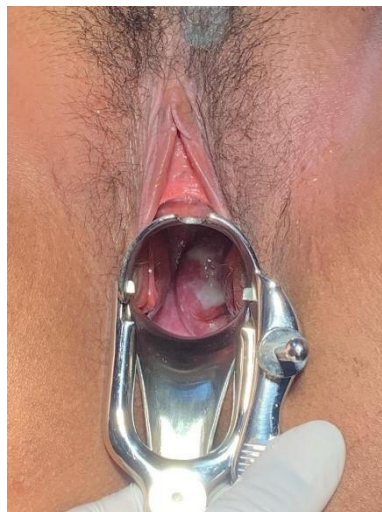


Figure 1. Gynecological Examination

Laboratory results and imaging were reviewed, revealing normal renal function, but urinalysis indicated a urinary tract infection. Chest X-ray revealed no abnormalities, with no signs of pulmonary tuberculosis or cardiomegaly.

Histopathological and Microbiological Results

The patient underwent cervical conization under spinal anesthesia. The excised tissue measured 2x2x5 cm and was sent for histopathological examination. Microscopic analysis revealed granulomatous inflammation with epithelioid histiocytes, Langhans giant cells, and caseous necrosis consistent with tuberculous cervicitis. Acid-fast bacilli were not detected on staining, and culture results were pending.

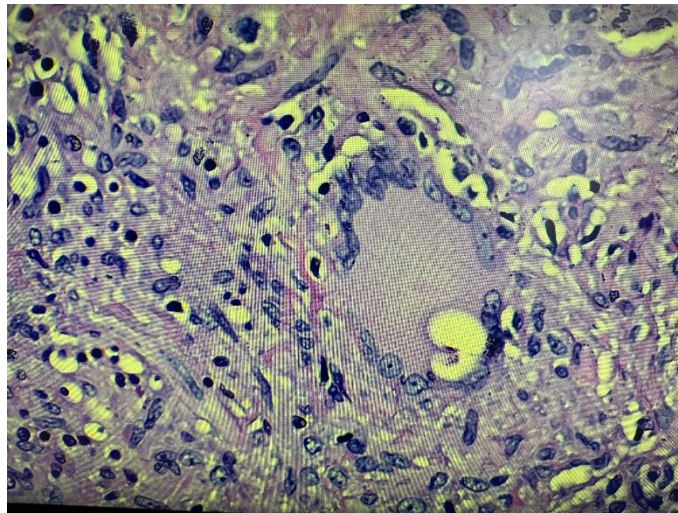


Figure 2. Hystology of the Cervix Showing Epithelioid Histiocytes, Langhans Giant Cells, and Caseous Necrosis

Treatment and Follow-up

Postoperatively, the patient was started on intravenous fluids and empirical antibiotics, including ceftriaxone and supportive medications. Antituberculous therapy (ATT) was initiated based on histopathological findings, following national TB treatment guidelines.

During hospitalization, the patient reported mild postoperative pain managed with analgesics. She was monitored closely for complications and showed gradual clinical improvement. At follow-up visits, symptoms of vaginal bleeding and discharge resolved, and no new complaints were reported.

DISCUSSION

Tuberculous cervicitis is a rare but clinically significant form of genital tuberculosis that often presents diagnostic challenges due to its nonspecific symptoms and its ability to mimic cervical malignancy.⁵ In the reported case of a 37-year-old female presenting with six months of vaginal bleeding and pain, accompanied by vaginal discharge, the clinical picture was initially indistinguishable from other causes of chronic cervicitis or even cervical cancer. The epidemiology of tuberculous cervicitis shows that it predominantly affects women of reproductive age, especially in TB-endemic regions.⁷ The infection usually spreads hematogenously from a primary focus such as pulmonary or abdominal tuberculosis, although direct extension and lymphatic spread are possible routes.⁵ The cervix is relatively resistant to infection due to its protective epithelial lining, but local trauma or immunosuppression can facilitate bacterial invasion.¹¹

Clinically, patients often present with abnormal vaginal bleeding, postcoital bleeding, and vaginal discharge, symptoms that overlap with cervical cancer and other gynecological conditions.^{5,7}

In this case, the absence of systemic symptoms such as fever, weight loss, or night sweats further complicated the clinical suspicion of tuberculosis. Physical examination in this patient revealed a cervix with yellowish leukorrhea but no visible ulceration or polypoid lesions, which is consistent with the variable presentation of tuberculous cervicitis.⁵ The lack of noticeable lesions underscores the importance of histopathological examination for definitive diagnosis.

Histopathology remains the gold standard for diagnosing tuberculous cervicitis. The presence of granulomatous inflammation with epithelioid histiocytes, Langhans giant cells, and caseous necrosis is characteristic.^{5,10} However, acid-fast bacilli are often not detected due to the paucibacillary nature of genital TB, which was also the case in this patient. The diagnostic challenge is compounded by conventional microbiological tests such as culture, which may take weeks and can be negative, necessitating reliance on clinical, histological, and radiological findings.^{7,10} In this case, chest X-ray was normal, indicating no active pulmonary TB, which is common in genital TB cases.

Treatment of tuberculous cervicitis involves standard antituberculous therapy (ATT) following WHO or national guidelines, typically including isoniazid, rifampicin, pyrazinamide, and ethambutol.^{10,11} The patient in this case was started on ATT after histopathological confirmation, which led to clinical improvement. Surgical intervention, such as cervical conization performed in this case, serves both diagnostic and therapeutic purposes. It allows tissue diagnosis and removal of localized lesions that may cause symptoms.^{10,11}

Early diagnosis and initiation of treatment are crucial to prevent complications such as infertility, chronic pelvic pain, and the spread of infection.⁷ Regular follow-up is necessary to monitor treatment response and to exclude coexisting malignancy. The rarity of tuberculous cervicitis and its clinical mimicry of cervical cancer necessitates a high index of suspicion, especially in endemic areas or in patients with risk factors such as previous TB exposure or immunosuppression.^{5,11}

Recent advances in molecular diagnostics and imaging have improved detection rates, but limitations remain due to the disease's subtle clinical presentation and paucibacillary nature.⁷ Integration of clinical, histopathological, and microbiological data remains essential. This case highlights the importance of considering tuberculous cervicitis in the differential diagnosis of chronic cervicitis, particularly when symptoms persist despite conventional treatment.

The absence of systemic symptoms in this patient, such as fever, weight loss, or night sweats, despite a confirmed diagnosis of tuberculous cervicitis, is a notable aspect often encountered in cases of genital tuberculosis. Genital TB, including its manifestation in the cervix, frequently presents as a localized form of extrapulmonary tuberculosis. The *Mycobacterium tuberculosis* bacilli usually reach the genital organs via hematogenous spread from a primary focus, which could be a distant site like the lungs or abdomen. If this primary lesion is dormant, healed, or the bacterial load that seeded the cervix is relatively low, significant systemic inflammatory responses typically associated with active pulmonary TB might not be triggered. The normal chest X-ray finding in this patient further supports the likelihood of isolated genital involvement without active pulmonary disease, a scenario commonly observed in genital tuberculosis cases.

Furthermore, the paucibacillary nature inherent to many cases of genital tuberculosis, including tuberculous cervicitis, plays a crucial role in the subdued systemic clinical picture. A low bacillary load means that the antigenic stimulus might be insufficient to provoke a pronounced systemic reaction that leads to overt symptoms like fever or cachexia. While the host's cell-mediated immunity is actively engaged at the local level, forming granulomas with epithelioid histiocytes and Langhans giant cells to contain the infection within the cervical tissue, this local containment might

effectively prevent wider dissemination that would otherwise elicit systemic symptoms. Consequently, the clinical presentation often remains insidious, with manifestations confined mainly to the local gynecological symptoms, such as abnormal bleeding or discharge, rather than a generalized tuberculous illness.

Prevalence of Tuberculous Cervicitis

Prevalence of Tuberculous Cervicitis Worldwide

Tuberculous cervicitis is a rare manifestation of female genital tuberculosis (FGTB), which itself accounts for about 5-10% of extrapulmonary tuberculosis cases globally. The prevalence of tuberculous cervicitis among genital TB cases is estimated to be around 5-10%, but exact global prevalence data are limited due to underreporting and diagnostic challenges.^{5,7} In high TB-burden countries, genital TB prevalence ranges from 1% to 19% among women presenting with infertility or chronic pelvic inflammatory disease, with cervical involvement being less common.⁷

The rarity of tuberculous cervicitis is partly due to the cervix's natural resistance to *Mycobacterium tuberculosis* infection. However, in endemic regions, clinicians should maintain a high index of suspicion, especially in women with chronic cervicitis symptoms unresponsive to conventional treatment.⁵

Prevalence of Tuberculous Cervicitis in Indonesia

Indonesia is among the countries with a high burden of tuberculosis, ranking in the top 10 globally, according to WHO reports. Female genital tuberculosis, including tuberculous cervicitis, is an important but often underdiagnosed cause of chronic pelvic infections and infertility in Indonesia.⁴ Studies in Indonesia report genital TB prevalence ranging from 1% to 7% among women with infertility or chronic pelvic inflammatory disease, with tuberculous cervicitis constituting a smaller subset of these cases.^{4,9} The limited availability of advanced diagnostic tools and the nonspecific clinical presentation contribute to underestimating the true prevalence. National TB control programs in Indonesia emphasize early detection and treatment, but genital TB remains a diagnostic challenge.⁸

Table 1. Prevalence of Tuberculous Cervicitis

Region	Genital TB Prevalence in Women with Infertility/Chronic PID	TB in Cervicitis Prevalence (of Genital TB)	References
Worldwide	1% - 19%	~5% - 10%	Russu et al., 2018; Singh et al., 2019
Indonesia	1% - 7%	Smaller subset (exact % not well defined)	Sari et al., 2022; Putri et al., 2021; WHO Indonesia TB Report, 2023

Pathophysiology of Tuberculous Cervicitis

Tuberculous cervicitis is a chronic granulomatous cervix inflammation caused by *Mycobacterium tuberculosis*. The pathophysiology begins when the bacilli reach the cervical tissue, usually through hematogenous spread from a primary focus such as the lungs, or less commonly via lymphatic spread or direct extension from adjacent pelvic organs.⁵ Once in the cervical tissue, *M. tuberculosis* triggers a cell-mediated immune response characterized by activating macrophages and T-lymphocytes. This immune response leads to the formation of granulomas, which are organized collections of epithelioid histiocytes, Langhans giant cells, and lymphocytes surrounding areas of caseous necrosis.⁷

The granulomatous inflammation causes tissue destruction and fibrosis in the cervix. The caseous necrosis results from the immune system's attempt to contain the infection and leads to local tissue damage. Over time, this process can cause ulceration, nodularity, and scarring of the cervical tissue, which may manifest clinically as abnormal vaginal bleeding, discharge, or cervical stenosis.¹⁰ The paucibacillary nature of genital tuberculosis means that the bacterial load is often low, making direct detection of bacilli difficult. However, immune-mediated tissue damage is significant and responsible for the clinical symptoms and complications associated with tuberculous cervicitis.

In addition, chronic inflammation may alter the normal cervical microenvironment, potentially affecting fertility and increasing susceptibility to secondary infections. Understanding the pathophysiology of tuberculous cervicitis is essential for clinicians to recognize the disease early and initiate appropriate antituberculous therapy to prevent irreversible tissue damage.

Clinical Manifestations of Tuberculous Cervicitis

Tuberculous cervicitis is a rare form of female genital tuberculosis that often presents with nonspecific and variable clinical symptoms, making diagnosis challenging. The most common clinical manifestations include abnormal vaginal bleeding, such as intermenstrual bleeding, menorrhagia, or postcoital bleeding.^{7,10} These symptoms often mimic those of cervical cancer or other chronic cervicitis causes. Patients may also present with persistent vaginal discharge, which can be serous, mucoid, or purulent, sometimes accompanied by a foul odor.⁵ Pelvic pain or discomfort is less common but may occur, primarily if pelvic inflammatory disease is associated.

The cervix may appear ulcerated, hypertrophied, or nodular on physical examination, and sometimes polypoid lesions are observed. These findings can closely resemble malignancy, leading to diagnostic confusion.⁷ Systemic symptoms such as fever, weight loss, and night sweats are often absent in isolated tuberculous cervicitis, further complicating clinical suspicion.¹⁰ However, in cases with concurrent pulmonary or disseminated tuberculosis, these systemic signs may be present.

Infertility and chronic pelvic inflammatory disease are potential long-term complications if the diagnosis is delayed or treatment is inadequate.¹⁰ Because of the nonspecific clinical presentation, tuberculous cervicitis is often diagnosed only after histopathological examination of cervical biopsy specimens, which reveal granulomatous inflammation characteristic of tuberculosis.

Management of Tuberculous Cervicitis

The management of tuberculous cervicitis primarily involves antituberculous therapy (ATT), the cornerstone of treatment. The standard regimen follows the World Health Organization (WHO) guidelines for tuberculosis treatment, typically consisting of an initial intensive phase of 2 months

with four first-line drugs: isoniazid, rifampicin, pyrazinamide, and ethambutol, followed by a continuation phase of 4 months with isoniazid and rifampicin.^{7,10} Early initiation of ATT is crucial to prevent the progression of the disease, reduce tissue destruction, and avoid complications such as cervical stenosis, infertility, or chronic pelvic pain. Treatment adherence and completion are essential to ensure a cure and prevent drug resistance.

Surgical intervention is generally reserved for diagnostic purposes, such as cervical biopsy or conization, and for managing complications like persistent cervical lesions or abscesses that do not respond to medical therapy.⁵ Surgery may also be necessary to exclude malignancy when clinical and histopathological findings are inconclusive. Supportive care includes symptomatic treatment for bleeding or discharge and monitoring for adverse drug reactions during ATT. Follow-up evaluations are important to assess treatment response clinically and, if needed, histologically.

In cases of drug-resistant tuberculosis, management becomes more complex and requires individualized treatment regimens based on drug susceptibility testing, often involving second-line antituberculous drugs.^{7,10} Multidisciplinary care involving gynecologists, infectious disease specialists, and pathologists enhances diagnostic accuracy and optimizes treatment outcomes.

CONCLUSION

Tuberculous cervicitis is a rare but clinically significant form of genital tuberculosis that often presents with nonspecific symptoms such as abnormal vaginal bleeding, postcoital bleeding, and vaginal discharge. These symptoms closely mimic those of cervical malignancy, making early diagnosis challenging. This case highlights the importance of maintaining a high index of suspicion, especially in TB-endemic regions or patients with relevant risk factors. Histopathological examination remains the gold standard for diagnosis, revealing characteristic granulomatous inflammation with epithelioid histiocytes, Langhans giant cells, and caseous necrosis. However, the paucibacillary nature of genital tuberculosis often results in negative acid-fast bacilli staining and culture, necessitating the integration of clinical, histopathological, and radiological findings for accurate diagnosis.

The pathophysiology involves hematogenous or lymphatic spread of *Mycobacterium tuberculosis* to the cervix, where chronic granulomatous inflammation leads to tissue destruction, fibrosis, and clinical manifestations. The cervix's natural resistance to infection explains the rarity of this condition, but local trauma or immunosuppression can facilitate bacterial invasion. Management primarily consists of standard antituberculous therapy (ATT) following WHO guidelines, typically including isoniazid, rifampicin, pyrazinamide, and ethambutol. Early initiation of ATT is crucial to prevent complications such as infertility, chronic pelvic pain, and cervical stenosis. Surgical intervention, such as cervical conization, may be necessary for diagnostic confirmation and symptom relief.

This case demonstrated favorable clinical outcomes with timely ATT and appropriate surgical management. Regular follow-up is essential to monitor treatment response and to exclude coexisting malignancy, given the clinical mimicry of tuberculous cervicitis with cervical cancer. The rarity of tuberculous cervicitis and its nonspecific presentation often lead to delayed diagnosis and inappropriate management, including unnecessary oncological procedures. Therefore, clinicians should consider tuberculous cervicitis in the differential diagnosis of chronic cervicitis, particularly in endemic areas or in patients with a history of tuberculosis exposure.

In this particular case, the diagnostic pathway involving cervical conization and subsequent histopathological examination proved crucial and appropriate for definitively identifying

tuberculous cervicitis. The subsequent management, centered on the timely administration of a standard antituberculous therapy regimen based on these findings, was correctly aligned with the confirmed diagnosis. This accurate diagnostic and therapeutic approach directly contributed to the successful resolution of the patient's clinical complaints, including the cessation of vaginal bleeding and discharge, highlighting that appropriate and early intervention leads to favorable outcomes.

Recent advances in molecular diagnostics and imaging have improved detection rates, but limitations remain due to subtle clinical presentation and the paucibacillary nature of the disease. Multidisciplinary care involving gynecologists, infectious disease specialists, and pathologists enhances diagnostic accuracy and optimizes treatment outcomes. In summary, tuberculous cervicitis, though rare, is an important differential diagnosis in chronic cervicitis cases. Early recognition, histopathological confirmation, and timely initiation of antituberculous therapy are key to achieving favorable patient outcomes and preventing serious complications.

REFERENCES

1. Laker S, Kibel M, Davies P. Cervicitis: A Review of Current Diagnosis and Management. *J Women's Heal Diagnostics*. 2023;
2. Network GH. The Burden of Cervical Infections Worldwide. *Lancet Glob Heal*. 2021;
3. Tanaka H, Lee S. Epidemiology of Infectious Cervicitis in Southeast Asia. *Asian J Obstet Gynecol*. 2022;
4. Sari RM, Putri DA, Wulandari D. Evaluation of Endometrial Tuberculosis among Subjects Undergoing Infertility Investigation in Indonesia. *Int J Health Sci (Qassim)* [Internet]. 2022; Available from: <https://www.neliti.com/publications/573684/evaluation-of-endometrial-tuberculosis-among-subjects-undergoing-endometrial-bio%0A>
5. Russu MC, Nastasia Ş, Degeratu D, Stănculescu R V. Breast and Cervix Uteri: Rare Locations for Mycobacterium Tuberculosis Infections and Complications - Cases Report and Literature Review. *IntechOpen* [Internet]. 2018; Available from: <https://www.intechopen.com/chapters/60981%0A>
6. Kesharwani H, Mohammad S, Pathak P. Tuberculosis in the Female Genital Tract. 2022;14(9):1–7. Available from: https://r.search.yahoo.com/_ylt=AwrKEjo1aEFoFQIAeELLQwx.;_ylu=Y29sbwNzZzMEcG9zAzEEdnRpZAMEc2VjA3Ny/RV=2/RE=1750326582/RO=10/RU=https%3A%2F%2Fpmc.ncbi.nlm.nih.gov%2Farticles%2FPMC9527183%2F/RK=2/RS=LU2Dup6ql0dvmIJJQNfvCDcy5hs-
7. Singh S, Singh A, Singh R. Cervical Tuberculosis: A Rare cause of Abnormal Vaginal Bleeding Mimicking Carcinoma Cervix. *J Clin Diagnostic Res* [Internet]. 2019; Available from: https://jcdr.net/article_fulltext.asp?issn=0973-709x&year=2019&volume=13&issue=11&page=QD06&issn=0973-709x&id=13296%0A
8. Organization WH. Indonesia Tuberculosis Profile [Internet]. 2023. Available from: <https://www.who.int/teams/global-tuberculosis-programme/data.%0A>
9. Putri AN, Santoso B. Female Genital Tuberculosis in Indonesia: Diagnostic Challenges and Treatment Outcomes. *Indones J Obstet Gynecol*. 2021;
10. Kumar A, Singh S, Sharma P. Immunopathogenesis of Female Genital Tuberculosis: A Review. *Int J Mycobacteriology* [Internet]. 2020; Available from: <https://www.ijmyco.org/article.asp?issn=2212-5531&year=2020&volume=9&issue=3&spage=215&epage=222&>

aulast=Kumar

11. Russu C, Degeratu D, Degeratu D, Stănculescu RV. Breast and Cervix Cervix Uteri : Uteri : Rare Rare Locations Locations for for Mycobacterium Tuberculosis Infections Infections and and Mycobacterium Tuberculosis Complications-Cases Report and Literature Review Complications-Cases Report and Literature R. 2020; Available from: https://r.search.yahoo.com/_ylt=AwrKGkoVaEFoWQIAQfLLQwx.;_ylu=Y29sbwNzZzMEcG9zAzIE dnRpZAMEc2VjA3Ny/RV=2/RE=1750326550/RO=10/RU=https%3A%2F%2Fcdn.intechopen.com%2Fpdfs%2F60195.pdf/RK=2/RS=Bz0PfHzhugTngSlzThWSgRNLTlw-