

## CASE REPORT: CHOANAL ATRESIA IN CHILDREN

Christopher Martinus Susanto<sup>1</sup>, Guntur Surya<sup>2\*</sup>

<sup>1</sup>Bagian Telinga, Hidung, dan Tenggorokan Fakultas Kedokteran Universitas Tarumanagara, Jakarta, Indonesia

<sup>2</sup>Departemen Telinga, Hidung, dan Tenggorokan, RS Sumber Waras, Jakarta, Indonesia

### ARTICLE INFO

**\*Corresponding author:**

Guntur Surya  
Departemen Telinga,  
Hidung, dan Tenggorokan,  
RS Sumber Waras, Jakarta,  
Indonesia

Email:  
guntur.surya@gmail.com

**Kata kunci:**

Atresia choanal bilateral  
Koanoplasti endonasal  
Neo-unichoanal

**Keywords:**

Bilateral atresia choana  
Endonasal choanoplasty  
Neo-unichoana

**Original submission:**

February 27, 2024;

**Accepted:**

March 11, 2024;

**Published:**

April 20, 2024;

### ABSTRAK

Atresia choanal merupakan kelainan dengan terdapatnya membran atau tulang kongenital dari satu atau kedua choanal akibat gagalnya membran bukonasalis untuk membelah sejak masa embrional. Saat ini masih terdapat kontroversi tentang efektivitas dari berbagai teknik bedah, perlunya penggunaan stent pasca bedah maupun agen anti-neoplastik. Memberikan informasi mengenai diagnosis dan tatalaksana atresia choanal. Perempuan berusia 15 tahun dengan atresia choanal bilateral. Pasien menjalani koanoplasti endonasal. Choanal paten sampai dengan evaluasi minggu ke-8 pasca operasi. Penatalaksanaan atresia choanal pembuatan neo-unichoanal dengan jabir mukosa merupakan salah satu teknik operasi yang efektif untuk penatalaksanaan atresia choanal

### ABSTRACT

**Case Report: Choanal Atresia in Children.** Choanal atresia is a disorder in which there is a congenital membrane or bone in one or both choanas due to the failure of the buconasalis membrane to divide from the embryonic period. Currently, there is still controversy about the effectiveness of various surgical techniques and the need for post-surgical use of stents and anti-neoplastic agents. Provides information regarding the diagnosis and management of choanal atresia. A 15-year-old female with bilateral choanal atresia. The patient underwent endonasal choanoplasty. Choanal was patented until the 8th week of post-operative evaluation. Management of choanal atresia. Making a neo-unicoana with a mucosal mesh is one of the effective surgical techniques for treating choanal atresia

## INTRODUCTION

Choana atresia is a disorder with a congenital absence of membrane or bone from one or both choana due to failure of the buccal membrane to divide during the embryonic period.<sup>1</sup> Choana atresia is divided into unilateral (10%) and bilateral (90%). Choana means any funnel-shaped cavity, or pair of openings between the nasal cavity and nasopharynx, also called choanae ossae and posterior nares.<sup>2</sup> Atresia means a congenital absence or closure of normal body orifices or tubular organs.<sup>3</sup>

In infants with bilateral choanal atresia, the patient may develop cyanosis and respiratory failure, as the infant must breathe through the nose to suck the nipple effectively. Bilateral choanal atresia is an emergency and should be treated immediately.<sup>4</sup> The incidence of choanal atresia is approximately 1 in 7000-8000 live births. The female-to-male ratio is 2:1, and unilateral and bilateral abnormalities are 2:1.<sup>5</sup>

Since it was first recognized in the eighteenth century, there is a wealth of literature describing various aspects of choanal atresia. However, there is still controversy about the effectiveness of various surgical techniques. Surgical techniques are still controversial due to the many complications of surgical techniques, limitations of existing literature for consensus on atresia choana surgery, and success rates that depend on the skill and experience of the operator. Transpalatal technique is the most widely used technique, but postoperative complications are quite common such as crossbite, palatal mesh damage, fistula, palatal muscle dysfunction, and velopharyngeal insufficiency.<sup>6</sup>

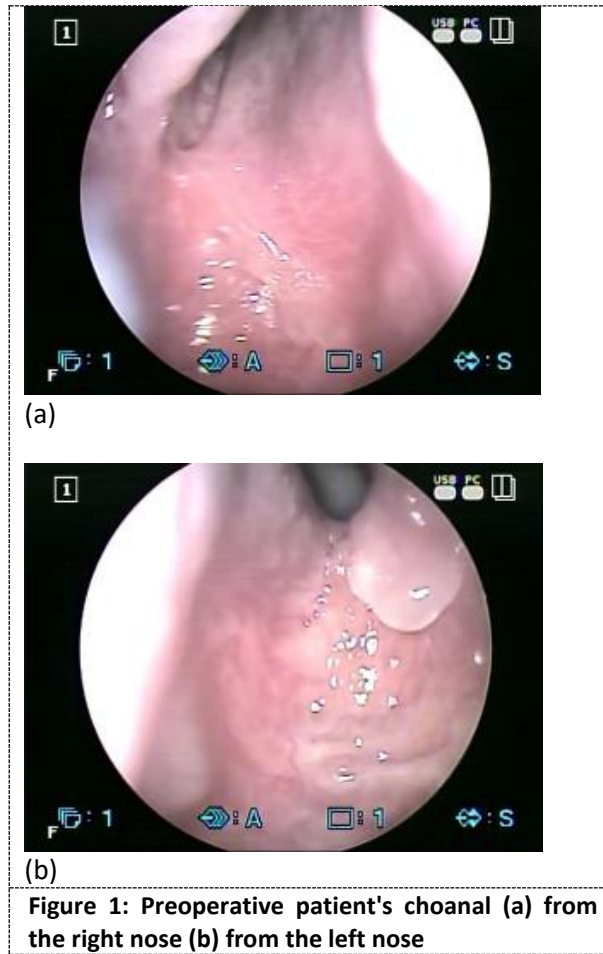
The use of stents after choana atresia surgery is also controversial. Some experts say that stents prevent restenosis and can stabilize the airway during recovery, but they can also cause infection and trigger the body's reaction to foreign bodies. Therefore, prophylactic antibiotics are recommended after stenting. The management of arterial choanal aims to restore nasal airflow without injuring structures that can interfere with craniofacial development with safe and effective surgical techniques.<sup>6</sup>

Reconstruction of choanal atresia was initially performed by simple blind transnasal puncture by Emmert in 1851 using Hegar or Fearson dilators. Transpalatal choanal atresia reconstruction was first described by Owens in 1965 as an approach to optimize the view of the atresia plate for reconstruction. The numerous complications of the transpalatal approach along with advances in endoscopes and microsurgical instruments allowed the development of endonasal for choana atresia reconstruction.<sup>4</sup> This paper aims to provide information on the latest developments in choanal atresia based on currently available literature.

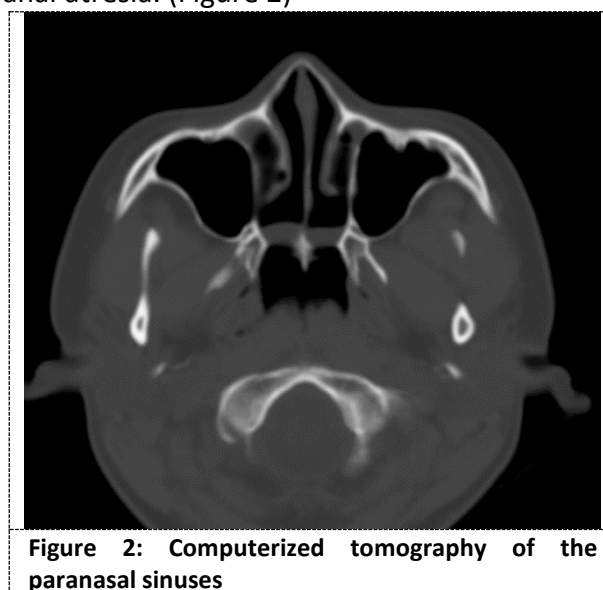
## CASE ILLUSTRATION

A 15-year-old female patient presented with complaints of not being able to breathe from the nose since birth accompanied by frequent yellow discharge with a liquid consistency, the amount of approximately 1 tissue, and odorless every time the patient looked down. The patient's mother said that since birth the patient breathed through the mouth, could not smell anything, made strong efforts to breathe so that there was a strong pull on the chest area, looked bluish when eating / breastfeeding, and returned to normal when crying. 5 years ago the patient had seen a previous doctor and was given a nasal spray. The discharge did not improve despite the nasal spray. The patient never sought treatment again due to financial constraints. One of the things that caused the patient to want to seek treatment again was that the patient was often teased by his friends. After all, he could not breathe through his

nose. On nasal drainage examination, there was no airflow. The nasoendoscopic examination revealed bilateral choanal atresia. (Figure 1)

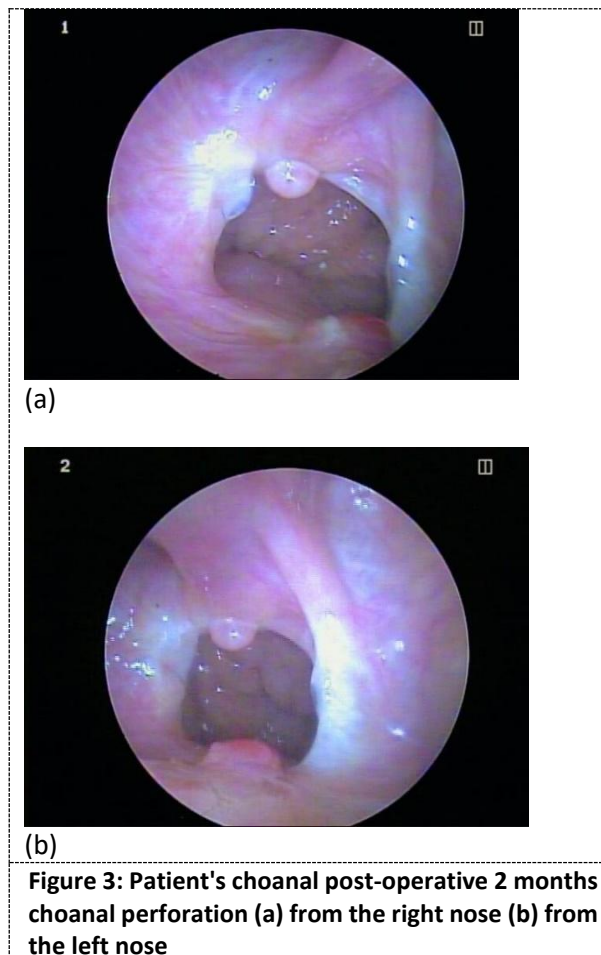


A computed tomography examination of the paranasal sinuses revealed bilateral membranous type choanal atresia. (Figure 2)



For management, endonasal coanoplasty surgery was performed with the "nasal septal crossover flap technique" and neo-unichoanal creation. The choice of endonasal choanoplasty technique was used because this technique has a fair success rate, and a large amount of literature, there are advances in endoscopic technology and advances in micro instrument technology. The flap method is also proven to prevent restenosis from the current literature.

After surgery, the patient claimed to be able to breathe. At 2 months after surgery, the choanal evaluation was still patent. (Figure 3).



## DISCUSSION

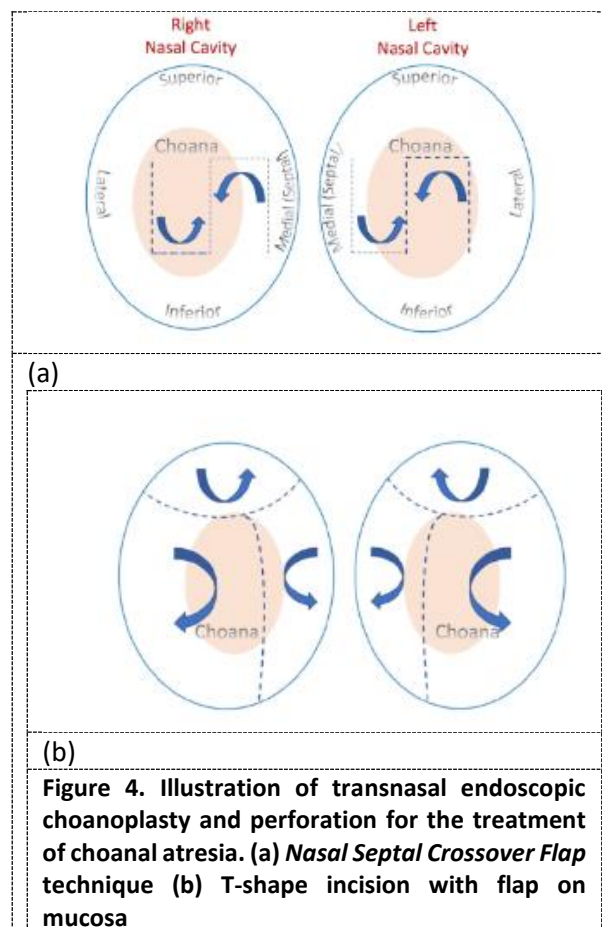
In 1775, choanal atresia was first described by Roederer. This disorder is a complete or partial obstruction of the posterior choanal (bone tissue or soft tissue (membrane)), which is persistent, and can occur unilaterally or bilaterally. Bilateral choanal atresia is often found at birth because it causes symptoms of respiratory distress. Newborns will breathe through the nose. If there is an obstruction in the airway, reflex breathing will occur through the mouth within a few weeks or months after birth. Neonates with bilateral choanal atresia breathe through the mouth, make strong efforts to inspire so that there is often chest retraction, often suck lips, will appear cyanotic in a calm state or when feeding / breastfeeding, and return to normal when crying. Unilateral atresia is usually undetectable, and the patient will have unilateral mucopurulent nasal discharge with persistent rhinorrhea

and intermittent obstruction symptoms. In choanal atresia, it is necessary to look for other abnormalities associated with CHARGE syndrome.<sup>7</sup>

In bilateral choanal atresia, emergency measures are needed by perforating the choanal to overcome airway obstruction, because neonates breathe mainly through the nose. In principle, there are four approaches to the surgical procedure, namely transnasal, transpalatal, transseptal, and transantral. Transnasal is performed when the atresia consists of a thin membrane or bone. The transpalatal procedure is performed when the atresia has a thick wall.<sup>8,9</sup>

The transnasal method uses an endoscope surgical instruments and drills. The stent is usually left in place for weeks after repair to prevent closure or stenosis.<sup>10</sup> Tracheostomy should be considered in cases of bilateral atresia where the child has other potentially life-threatening problems and where early surgical repair of choanal atresia may be inappropriate or impossible.<sup>11</sup>

The flap method can prevent restenosis. Restenosis can usually occur in bilateral bone-type choanal atresia. Many techniques of mucosal incision form are described by many studies. For example, the "*nasal septal crossover flap technique*" is performed via transnasal micro-endoscopic.<sup>8</sup> In this flap method, an L-shaped incision is made that divides the mucosa into superior and inferior mucosal folds. The success rate is 86% for unilateral cases and 72% for bilateral cases (Figure 4). There is also a T-shaped mucosal incision technique made using a pointed cautery tip with a vertical tip of the letter T. There is a considerable success rate without restenosis in the T-incision technique (Figure 4).<sup>9,12</sup>



In this case, the patient adapted as an infant by breathing with her mouth. This persisted until the patient was a teenager as the patient and family were more focused on managing the discharge from the nose and thought the reason why the patient could not breathe was due to the amount of discharge in the nose.<sup>13</sup> *Stents* have been used as adjunctive therapy in choanal atresia reconstruction since Stankiewicz first performed endonasal reconstruction. *Stents* are used to prevent restenosis and as an airway. A survey in 2000 showed that 93% of surgeons used *stents* after choana atresia reconstruction. However, recent studies have shown that choanal atresia reconstruction can be safely performed without the use of *stents*. Strychowsky in meta-analysis study stated that there was no significant difference in postoperative *stent* use on surgical success, but *stent* use caused more complications.<sup>13</sup>

Mitomycin C is a topical aminoglycoside antibiotic used to reduce scar and granulation tissue formation by inhibiting the growth and migration of fibroblast growth factors. Holland first reported the successful use of mitomycin in choanal atresia in 2001. Systematic reviews have shown that mitomycin provides good results in laryngeal and tracheal surgery but its effectiveness for preventing restenosis and granulation tissue in choanal atresia is still highly variable.<sup>14</sup>

The 2012 Cochrane Review reached similar conclusions regarding the limitations of the existing literature on choanal atresia reconstruction and recommended multicenter RCT studies on the effectiveness and safety of various surgical techniques for choanal atresia reconstruction.<sup>15</sup>

Another approach to optimize visualization of the atresia plate for reconstruction can be transpalatal choanal atresia reconstruction as first described by Owens in 1965. However, potential complications of this approach such as *crossbite*, palatal mesh damage, fistula, palatal muscle dysfunction, and velopharyngeal insufficiency make this approach not recommended in children less than 6 years old.<sup>11</sup>

Choanal atresia is a relatively rare but well-recognized disorder characterized by the anatomical closure of the posterior choanal. There is no consensus on surgical techniques for the reconstruction of choanal atresia due to limited literature. The current management of choanal atresia is an endonasal approach using a pediatric endoscope and micro-instruments, while the use of topical mitomycin and postoperative *stents* to date has not been found to make a significant difference from various studies that have been conducted. Physiologic saline irrigation and routine postoperative endoscopic evaluation are important factors for the successful primary reconstruction of choanal atresia.<sup>16</sup>

Based on the literature to date, the management of atresia choana with neo-unicoana creation with mucosal mesh is one of the effective surgical techniques and has a high success rate.<sup>16</sup>

## CONCLUSION

Management of choanal atresia neo-unicoana creation with mucosal mesh is one of the effective surgical techniques for the management of choanal atresia. Although no stenting was performed, there were no complications 2 months postoperatively.

**REFERENCES**

1. Günel C, Başak S, Toskala E. Congenital Malformations of the Nose and Paranasal Sinuses. *All Around the Nose: Basic Science, Diseases and Surgical Management*. 2020;171–7.
2. Paulsen F, Böckers TM, Waschke J, Winkler S, Dalkowski K, Mair J, et al. *Sobotta anatomy textbook: English edition with Latin nomenclature*. Elsevier Health Sciences; 2018.
3. Srikanthan A, Scott S, Desai V, Reichert L. Neonatal airway abnormalities. *Children*. 2022;9(7):944.
4. Indrawati LPL, Riski MS, Parjaman R. Bilateral choanal atresia. *Oto Rhino Laryngologica Indonesiana*. 2021;51(2).
5. Benjamin RH, Marengo LK, Scheuerle AE, Agopian AJ, Mitchell LE. Prevalence and descriptive epidemiology of choanal atresia and stenosis in Texas, 1999–2018. *Am J Med Genet A*. 2024;e63549.
6. Stankiewicz JA. Endoscopic repair of choanal atresia: 33 years later. *Ear Nose Throat J*. 2021;100(9):629–30.
7. Urbančič J, Vozel D, Battelino S, Boršoš I, Bregant L, Glavan M, et al. Management of choanal atresia: national recommendations with a comprehensive literature review. *Children*. 2023;10(1):91.
8. van Schaik CGR, Paasch S, Albrecht T, Becker S. Treatment of choanal atresia in a cohort of 29 patients: Determinants for success or failure. *Int J Pediatr Otorhinolaryngol*. 2022;160:111240.
9. Ouattassi N, Wissam El, Asmae A, Zaki Z, El Alami MN. Current Management of Congenital Choanal Atresia: Litteratur Review. *Indian Journal of Otolaryngology and Head & Neck Surgery*. 2023;75(3):2227–34.
10. Sabale AS, Kulkarni AD, Sabale AS. Nasal In Situ Gel: Novel Approach for Nasal Drug Delivery. *Journal of Drug Delivery and Therapeutics*. 2020 Apr 15;10(2-s):183–97.
11. Ibnu YS, Kristyono I. UNUSUAL CHOANAL ATRESIA IN CHILDREN. *Folia Medica Indonesiana (2355-8393)*. 2022;58(3).
12. Alsubaie HM, Almosa WH, Al-Qahtani AS, Margalani O. Choanal Atresia Repair With Stents and Flaps: A Systematic Review Article. *Allergy & Rhinology*. 2021;12:21526567211058052.
13. Margalani O. Choanal Atresia Repair With Stents and Flaps: A Systematic Review Article. 2021;
14. Aldriweesh B, Alshareef W, Alsini A, Aljasser A, Alammar A. Safety profile and efficacy of high-dose topical mitomycin-C for choanal atresia repair: A prospective cohort study. *Int J Pediatr Otorhinolaryngol*. 2022;159:111190.
15. Strychowsky JE, Kawai K, Moritz E, Rahbar R, Adil EA. To stent or not to stent? A meta-analysis of endonasal congenital bilateral choanal atresia repair. *Laryngoscope*. 2016 Jan 25;126(1):218–27.
16. Cedin AC, Atallah ÁN, Andriolo RB, Cruz OL, Pignatari SN. Surgery for congenital choanal atresia. *Cochrane Database of Systematic Reviews*. 2012 Feb 15;