

## THE IMPACT OF SEIZURES ON COGNITIVE ABILITIES OF PATIENTS DIAGNOSED WITH NEUROCYSTICERCOSIS: A SYSTEMATIC REVIEW

Noveline Sagita<sup>1,2</sup>, Putri Thalia Handoko<sup>2</sup>, Ardo Sanjaya<sup>3</sup>, Julia Windi Gunadi<sup>4\*</sup>

<sup>1</sup>Neurology Department, Immanuel Hospital, Bandung

<sup>2</sup>Faculty of Medicine, Maranatha Christian University, Bandung, Indonesia

<sup>3</sup>Anatomy Department, Faculty of Medicine, Maranatha Christian University, Bandung, Indonesia

<sup>4</sup>Physiology Department, Faculty of Medicine, Maranatha Christian University, Bandung, Indonesia

### ARTICLE INFO

#### \*Corresponding author:

Julia Windi Gunadi  
Physiology Department  
Faculty of Medicine  
Maranatha Christian  
University  
Bandung, Indonesia

Email:

julia.windi@maranatha.ac.id

#### Kata kunci:

Neurocysticercosis  
Kejang  
Kemampuan kognitif

#### Keywords:

Neurocysticercosis  
Seizure  
Cognitive function

#### Original submission:

February 1, 2024;

#### Accepted:

March 25, 2024;

#### Published:

April 10, 2024

### ABSTRAK

Neurocysticercosis merupakan salah satu penyakit infeksi akibat parasit yang paling sering ditemukan. Penyakit ini disebabkan oleh infeksi dari larva (sistiserkus) cacing pita *Taenia solium* pada sistem saraf pusat. Salah satu manifestasi klinis dari kondisi ini adalah kejang berulang yang dapat menyebabkan terjadinya kerusakan pada jaringan otak dan fungsinya. Studi pustaka ini bertujuan untuk membahas pengaruh kejang terhadap kemampuan kognitif pasien yang terdiagnosis neurocysticercosis. Metode yang digunakan adalah *systematic review* dengan menggunakan search engine (Pubmed and The Cochrane Library) dengan menggunakan kata kunci "*neurocysticercosis*" dan "*seizure*" dan "*cognitive*". Kriteria inklusi pada studi pustaka ini meliputi artikel yang diterbitkan dalam 10 tahun terakhir dengan akses teks lengkap. Kami menemukan 6 artikel yang membandingkan kemampuan kognitif pasien terdiagnosis neurocysticercosis dengan kontrol sehat. Dari studi pustaka ini, dapat disimpulkan bahwa pasien neurocysticercosis cenderung memiliki kemampuan kognitif yang lebih rendah pada beberapa aspek tertentu jika dibandingkan dengan kontrol sehat.

### ABSTRACT

**The Impact of Seizures on Cognitive Abilities of Patients Diagnosed with Neurocysticercosis.** Neurocysticercosis is one of the most encountered infectious diseases caused by parasites. This condition is caused by an infection of the larvae (cysticercus) of the tapeworm *Taenia Solium* in the central nervous system. One of the many clinical manifestations of this condition is recurrent seizures that can eventually lead to damage to brain tissue and its functions. This literature review aims to discuss the effect of seizures on the cognitive function of patients diagnosed with neurocysticercosis. The method used in this study is a systematic review with search engines (PubMed and the Cochrane Library) using the keywords "*neurocysticercosis*" and "*seizure*" and "*cognitive*". Inclusion criteria for this literature review include articles and journals published in the last 10 years with full-text access. We found 6 articles comparing the cognitive abilities of neurocysticercosis-diagnosed patients with healthy control. This literature review concluded that neurocysticercosis patients tend to have lower cognitive function in certain aspects compared to healthy controls.

## INTRODUCTION

Neurocysticercosis (NCC) is a chronic condition caused by the presence of cysts containing larvae or cysticerci of the *Taenia solium* tapeworm in the human central nervous system (CNS).<sup>1</sup> This condition can result from the consumption of undercooked pork that has been infected by *Taenia solium* tapeworm.<sup>2</sup> Neurocysticercosis is endemic in many developing countries, particularly in Latin America, the Indian subcontinent, Southeast Asia, sub-Saharan Africa, and parts of China.<sup>3,4</sup> About 10-20% of the population in these endemic areas has either experienced or is currently experiencing neurocysticercosis.<sup>5</sup>

Neurocysticercosis is not limited to adult patients but can also be found in pediatric cases.<sup>6</sup> This condition can be asymptomatic, but symptomatic cases of neurocysticercosis are not uncommon.<sup>7</sup> The clinical manifestations vary widely, depending on the number, size, stage, and location of the cysticerci in the patient's central nervous system (CNS).<sup>8</sup> Some commonly encountered clinical manifestations in neurocysticercosis cases include nausea, vomiting, fever, headaches, and a decrease in consciousness.<sup>9</sup> In more severe cases, repeated seizures are usually found. Each year, neurocysticercosis underlies approximately one-third of 90% of seizures in adults<sup>10</sup> and about 43% of seizures in children worldwide.<sup>9</sup>

Seizures resulting from neurocysticercosis can lead to irreversible damage to brain tissue, triggering a decline in brain function.<sup>11</sup> Therefore, this literature review aims to discuss and compare the damage and decline in brain function, especially cognitive abilities, in patients diagnosed with neurocysticercosis.

## METHOD

The method used is a systematic review, involving the analysis of secondary data gathered from various national and international articles and journals using keywords such as "neurocysticercosis" **and** "seizure" **and** "cognitive" on PubMed and the Cochrane Library.

The inclusion criteria for our systematic review were as follows: (1) Journals or articles, (2) that were published within the last 10 years, (3) have full access, (4) conducted research on the cognitive function of NCC patients. The systematic review process begins with searching for articles and journals based on the relevant keywords, adhering to the inclusion criteria mentioned above. Screening is then conducted on the found articles and journals by adjusting the relevance of titles, abstracts, and discussions to the objectives of the systematic review. The flow diagram of article selection for the review is shown in Figure 1.

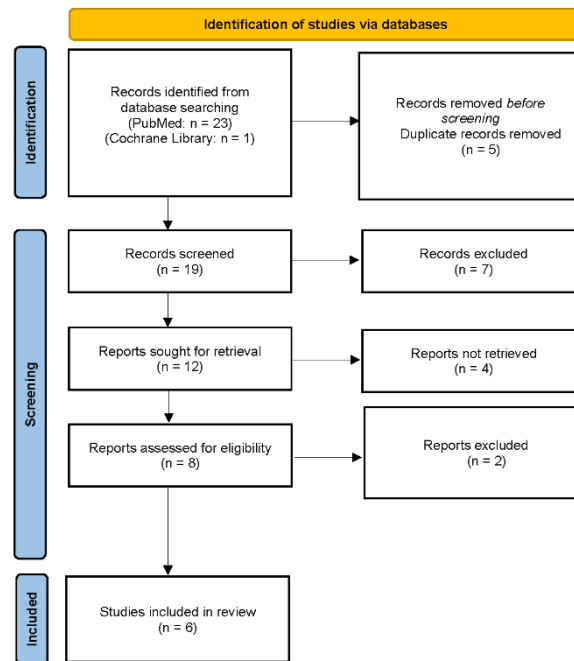


Figure 1. Flow Diagram of Article Selection

Articles and journals that meet the criteria and align with the purpose of the review are then extracted into a table containing author names, publication year, research subject, and relevant findings. Finally, an analysis, discussion, and conclusion are drawn from the extracted articles and journals.

## RESULT

From the literature search results, six articles meeting the criteria were found for further analysis and discussion. The extracted data from these six articles can be seen in Table 1 below.

Table 1. Research Findings on The Impact of Seizures on Cognitive Abilities in Patients Diagnosed with Neurocysticercosis

Author (Year)	Research Subjects	Research Results
Pratibha, <i>et al</i> , 2018 <sup>12</sup>	500 patients	This study aims to assess the academic performance and cognitive abilities of children with parenchymal neurocysticercosis. Academic performance is evaluated using the learning outcomes obtained by children during formal education, while cognitive abilities are assessed using the Draw-a-Man test. The results of this study indicate that approximately one-fourth (25%) of the total research subjects experience cognitive impairments that affect the academic performance of children.
Rajniti, <i>et al</i> , 2014 <sup>13</sup>	83 patients	This study aims to assess the cognitive abilities and behavior of children with neurocysticercosis (NCC). Cognitive assessment is conducted using the Binet-Kulshreshtha Test, while behavior assessment is carried out using Achenbach's Behavior Child Checklist (CBCL). The conclusion of this study is that children with NCC tend to have lower IQ compared to generally healthy children. Behavioral issues, such as aggressive behavior, are also more frequently observed in children with NCC.

Anjali, <i>et al</i> , 2018 <sup>14</sup>	35 patients	This study aims to compare the intelligence level and behaviour of untreated children diagnosed with NCC with healthy peers. Intelligence assessment is conducted using Malin's Intelligence Scale for Indian Children (MISIC), while behaviour assessment is carried out using Childhood Behavioural Checklist (CBCL). The study concludes that the intelligence level of untreated children with neurocysticercosis is equivalent to that of healthy children at the same age. The research also concludes that there is no significant behavioural disturbance found in children with NCC.
Oscar, <i>et al</i> , 2019 <sup>15</sup>	79 patients	This study aims to explore the relationship between neurocysticercosis cases with calcified cysts and the decline in patient cognitive function, along with its relevance to hippocampal atrophy. As a result, it was found that neurocysticercosis patients may experience a decline in cognitive function, possibly due to hippocampal atrophy, particularly in elderly patients.
Nau, <i>et al</i> , 2017 <sup>16</sup>	47 patients	This research aims to investigate whether there is a decline in cognitive function and Quality of Life (QoL) in patients with epilepsy with or without neurocysticercosis. Several tests were conducted in this study to assess the cognitive function of patients, including the Mini Mental State Examination (MMSE), The Selective Reminding Test (SRT), The Spatial Recall Test (SPART), The Digit Span, and the Alertness test. Meanwhile, the WHOQOL-BREF questionnaire was used to assess QoL. From this research, it is known that epilepsy patients, both with and without neurocysticercosis, tend to have lower neuropsychological abilities and QoL levels compared to healthy controls. Additionally, the study also indicates that epilepsy patients without NCC are more likely to experience a more drastic decline in cognitive function and QoL compared to patients with NCC.
Johnson, <i>et al</i> , 2022 <sup>17</sup>	103 patients	This study aims to evaluate the effectiveness of Albendazole therapy in treating NCC, both for 7 days and 28 days. Several aspects were assessed in this study, including radiological findings, cognitive abilities, and school performance. The results of the study indicate that the duration of Albendazole therapy for 7 or 28 days yields similar outcomes, with progressive reduction in lesion size, resolution, and calcification observed. Additionally, the research findings also indicate that the majority of patients with NCC experience a decline in cognitive function, as well as psychiatric disorders such as dementia, depression, psychosis, and behavioral abnormalities.

## DISCUSSION

### Seizures in Neurocysticercosis.

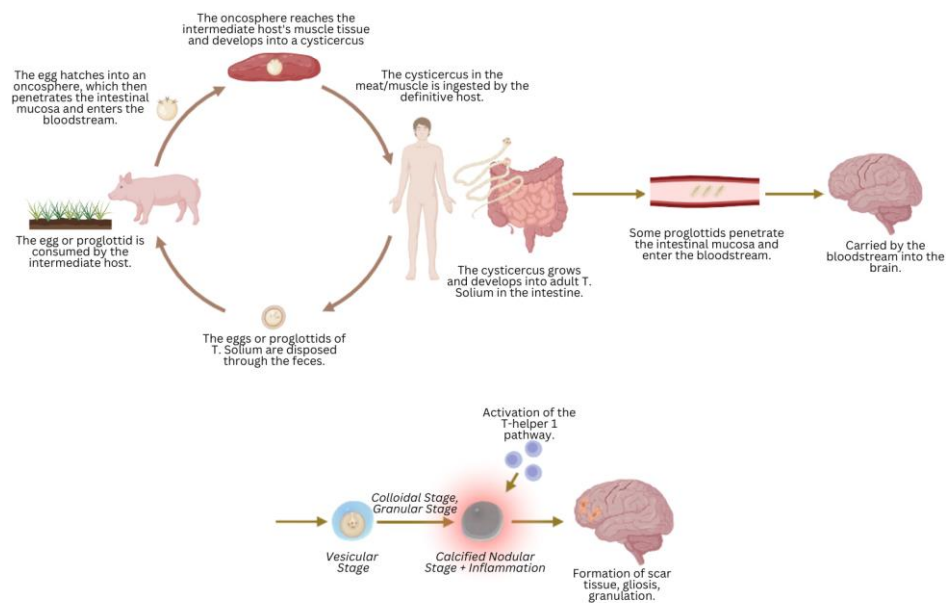
Neurocysticercosis is a chronic infection of the central nervous system caused by pork tapeworm (*Taenia solium*).<sup>18</sup> There are two hosts for *T. solium*, one is pig, and the other is human, both served as definitive and intermediate hosts, through fecal-oral transmission.<sup>18</sup> Most people with neurocysticercosis did not show any symptoms at all (asymptomatic)<sup>5</sup>, but in some individuals, the symptoms might manifest as seizures/epilepsy, headache and intracranial hypertension, focal neurologic deficits, and also a cognitive decline.<sup>19</sup> In developing countries and endemic areas, such as Latin America, the Indian subcontinent, Southeast Asia, sub-Saharan Africa, and parts of China<sup>2-4</sup>, cysticercosis in humans are caused by pork worm carriers, poor hygiene and sanitation, and undercooked pork consumption, influenced by low social economy status.<sup>19</sup> The diagnosis of neurocysticercosis can be established using Del Brutto's diagnostic criteria, which consist of absolute criteria, neuroimaging criteria, and clinical/exposure criteria.<sup>20</sup>

Generally, seizures or convulsions are a condition that occurs due to temporary disruptions in the electrical activity of the brain tissue. This condition manifests with various symptoms, but commonly observed indications include excessive muscle contractions, muscle stiffness, involuntary movements, decreased consciousness, and even post-ictal confusion—a state where the patient feels drowsy, confused, and unfocused after the seizure has ended.<sup>18</sup> Seizures are one of the most commonly encountered clinical manifestations in cases of chronic neurocysticercosis. In the early stages of the disease, patients typically do not show any symptoms (asymptomatic) due to the extended incubation period of the *Taenia Solium* larva, coupled with the defense mechanisms possessed by the parasite itself.<sup>2,7</sup> However, after several years, the cyst containing the *T. Solium* larva (cysticercus) will become actively developed, eventually undergoing degeneration.<sup>3</sup> This process triggers inflammation in the patient's brain tissue and the surrounding areas.<sup>19</sup>

The combination of lesion location and stage will result in various distinct clinical manifestations. Generally, neurocysticercosis types can be differentiated based on the cyst location, either in the brain parenchyma (single or multiple) or in the extra parenchymal region (intraventricular or subarachnoid space).<sup>21,22</sup> Lesions in the form of granulomas or cysts in the parenchyma commonly lead to seizures and chronic headaches. If the cyst is large, neurological deficits may also be present. Cognitive or memory impairment and psychiatric disturbances are frequently observed as well.<sup>21,21</sup> Cysts located in the parenchyma are generally smaller, with a diameter rarely exceeding 2 cm. On the other hand, extra parenchymal cysts, such as those in the subarachnoid space, can extend to the surrounding area, causing mass effects, hydrocephalus, chronic arachnoiditis, and vasculitis. Extra parenchymal cysts also tend to have a poorer prognosis.<sup>22</sup>

The developmental process of cysticercosis *T. Solium* cysts in parenchymal neurocysticercosis can be divided into four stages (Escobar staging): the vesicular stage, colloidal stage, granular stage, and calcified nodular stage can be seen in Figure 2.<sup>23</sup> The vesicular stage occurs during the first 3-6 years, where the cyst containing active cysticercosis from *Taenia Solium* settles in the patient's central nervous system, specifically in the brain parenchyma, and undergoes maturation.<sup>4</sup> In this stage, the cyst employs several defense mechanisms to protect itself from the host's immune system, including the release of glycoconjugates, immunomodulation, inactivation of the host complement pathway by binding paramyosin from cysticercosis with C1q components, and others (Figure 2).<sup>2</sup>

After several years, the cyst initially containing active cysticercosis will start undergoing hyaline degeneration in the colloidal stage. This stage is characterized by thickening of the cyst wall and a change in the cyst's contents to a gelatinous, opaque fluid.<sup>7</sup> As time progresses, the cyst will enter the granular stage, characterized by contraction of the cyst, accompanied by thickening of the cyst wall, which will then progress to necrosis and calcium deposition. Finally, the cyst will undergo complete calcification in the calcified nodular stage (Figure 2).<sup>9</sup>



**Figure 2. Pathogenesis of Neurocysticercosis**

The calcification process of cysticercosis cysts from the colloidal stage to the calcified nodular stage can cause inflammation and triggers the host's immune response<sup>23</sup>, particularly the activation of the T-helper 1 (Th-1) pathway. This activation can lead to the formation of scar tissue (gliosis) and granulomas around the cyst.<sup>2,19</sup> Some studies suggest that the formation of these structures, along with active inflammatory processes (edema), is one of the causes of seizures in neurocysticercosis cases.<sup>23</sup> The progression of neurocysticercosis, from the cysticercus in the consumed meat/muscle by the definitive host (human) to the formation of scar tissue in the brain, can be observed in Figure 2. Seizures in neurocysticercosis patients can occur at any stage of cyst development. Local inflammation around the cyst, as well as calcification, scarring, or perilesional gliosis around the cyst, are risk factors for the occurrence of recurrent seizures later.<sup>8</sup>

In patients with granulomas, seizures arise because of blood-brain barrier damage following inflammation associated with the host's immune defense against the cyst. In patients with calcification, cysticercal antigens are trapped in the calcified nodules then react with host antibodies, leading to seizures.<sup>21</sup> Seizures associated with neurocysticercosis are considered acute symptomatic, meaning that seizures will subside when the inflammation diminishes. However, it is important to note that the parasite in the granular and calcification stages can become epileptogenic foci and cause recurrent seizures without provocation if the patient is not provided

with antiepileptic therapy. Several imaging studies indicate a relationship between neurocysticercosis and damage to the brain tissue.<sup>22</sup> The seizures that commonly occur in neurocysticercosis patients can be categorized into two types: generalized tonic-clonic seizures (GTCS)<sup>9</sup> and focal seizures. In neurocysticercosis, seizures typically have a focal onset and then rapidly evolve into bilateral tonic-clonic seizures. Epilepsy in cases of neurocysticercosis falls under the category of acquired epilepsy as it is caused by pathological factors.<sup>22</sup> These seizures typically occur with a relatively short duration, usually less than five minutes<sup>7</sup>. Despite their short duration, neurocysticercosis patients with recurrent seizures still have a high risk of brain tissue damage, and this can impact the patient's cognitive abilities and brain function.

### ***Cognitive Decline in Neurocysticercosis Patients***

**Cognitive Decline in Neurocysticercosis.** Based on a study conducted by Pratibha Singhi et al. on 500 pediatric patients with parenchymal neurocysticercosis, it was found that approximately 40.2% of the patients still frequently experience symptomatic manifestations despite the neurocysticercosis diagnosis being established seven years prior. Around 17.4% of the patients frequently experience recurrent seizures, and approximately 40.2% still complain of symptoms such as headaches (13.6%), decreased memory (14%), and even behavioral disturbances (7.6%). Patients with multiple cystic lesions (63.7%) tend to experience more severe damage and symptoms compared to patients with single lesions. The primary parameter in this study is cognitive function, where about 22.2% (or equivalent to 111 patients) of neurocysticercosis patients were found to have a significant decline in academic performance. Additionally, it was discovered that around 30.6% of patients experienced a decrease in academic interest, and approximately 18.2% of patients had a decrease in IQ scores to <70, indicating mild intellectual disability.

The second study conducted by Rajniti Prasat et al involved 83 patients with neurocysticercosis. In this research, it was found that 51.8% of neurocysticercosis patients experienced generalized tonic-clonic seizures, 24.1% had complex partial seizures, 15.8% had simple partial seizures, and 8.4% had tonic seizures. In the majority of the study subjects, specifically in 52 subjects (62.7%), cystic lesions were found in the parietal lobes. This study discovered that neurocysticercosis patients tend to have lower IQ scores compared to controls, especially in aspects of conceptual understanding, analysis and reasoning, verbal ability, as well as memory and spatial abilities. Additionally, in neurocysticercosis patients with clinical manifestations of seizures, behavior problems such as anxiety disorders, depression, somatic disorders, and social disturbances were also observed. The next study by Anjali Verma et al., involved 35 subjects. In this study, it was found that 45.7% of the subjects experienced generalized seizures, while 54.3% had focal seizures. The most common location for neurocysticercosis cystic lesions was the parietal lobe (54.2%), followed by the frontal lobe (31.4%), temporal lobe (8.5%), and occipital lobe (5.7%). The results of this study indicated a decline in brain function in neurocysticercosis patients, particularly in aspects of information processing, comprehension, and verbal abilities. Additionally, neurocysticercosis patients also tended to experience disturbances and a decline in abilities related to conceptual understanding, analysis, reasoning, as well as verbal, memory, and spatial abilities.

Oscar H Del Brutto et al. in 2019 conducted another study, which involved 79 subjects aged 40 years or older diagnosed with neurocysticercosis who had undergone CT-scan and MRI examinations.<sup>21</sup> Cysticercosis cysts that had calcified and were surrounded by gliosis were found in all subjects, with 59 subjects having a single cyst, 16 subjects having 2 to 3 cysts, and 4 patients having more than 4 cysts. Upon further examination, it was discovered that 28 study subjects

experienced hippocampal atrophy. This atrophy was found in subjects older than 68 years compared to other subjects. In addition to the subjects, hippocampal atrophy was also found in 10 healthy controls of similar age ( $\geq 68$  years). It can be observed that in the same age group, subjects with neurocysticercosis were more likely to experience hippocampal atrophy compared to healthy controls. Furthermore, in patients with cysticercosis cysts, a decline in cognitive abilities was also observed, and this decline was more significant in subjects with hippocampal atrophy.<sup>21</sup>

The study conducted by Anne L. Nau et al aimed to compare the Quality of Life (QoL) and cognitive abilities of epilepsy patients with NCC, epilepsy patients without NCC, and healthy controls. All epilepsy patients in this study were not undergoing adequate anti-epileptic therapy. The results of this study showed that patients with epilepsy had significantly lower cognitive abilities compared to healthy controls. However, upon further examination, epilepsy patients without NCC were found to have poorer performance in three out of five cognitive ability tests compared to epilepsy patients with NCC. In addition to cognitive abilities, epilepsy patients, both with and without NCC, had much lower QoL compared to healthy controls.<sup>24</sup>

There is also a study by Nameirakpam Johnson et al. that examined 103 children with NCC and seizures undergoing Albendazole therapy as an antiparasitic treatment. These children were divided into 2 groups: Group A, receiving Albendazole therapy for 7 days (55 children), and Group B, receiving therapy for 28 days (48 children). Subsequently, the researchers evaluated the radiological findings, cognitive abilities, and school performance of all children and compared the results between the two groups. In terms of radiological findings, both groups showed a progressive reduction in the average lesion size, leading to faster resolution and calcification. However, patients from Group B tended to experience seizure recurrence more frequently (20.8%) compared to patients from Group A (20%). This recurrence typically occurred in the first year, or sometimes after 3 years of follow-up. In terms of cognitive abilities, it was discovered that all patients had average or below-average IQ levels, but no significant differences were observed between the two groups. Likewise, there were no significant differences found between the groups regarding school performance. In this study, more than half of the total children studied had low or below-average IQ levels. Around one-tenth of these children experienced difficulties in reading, writing, mathematics, and socializing with peers. Additionally, behavioral abnormalities such as anxiety, depression, withdrawal, somatic and social issues, and rule-breaking behavior were not uncommonly found. This study concludes that NCC has a negative impact on cognition, behavior, and school performance.<sup>25</sup>

Information obtained from the six studies above is consistent with findings from various literature. Neurocysticercosis as a cause of seizures is also found in Indonesia. A serial case report on neurocysticercosis from Bali indicates that seizures are the most common manifestation, alongside headaches.<sup>24</sup> However, the discussion about neurocysticercosis as a cause of epilepsy leading to cognitive impairment has not been extensively explored. Until now, there is still debate about whether neurocysticercosis only triggers acute seizure reactions or can lead to epilepsy. However, some studies indicate that calcified lesions are associated with hippocampal sclerosis, which is one of the causes of epilepsy. Moreover, the chronic inflammatory processes that result in scar tissue formation in the brain parenchyma have the potential to cause persistent seizures.<sup>3</sup>

A study on animal models indicates that neurocysticercosis leads to a decline in working memory and a reduction in neuronal density in the hippocampus.<sup>25</sup> Another study indicates that in patients with neurocysticercosis, there is an increase in acetylcholinesterase levels in cerebrospinal fluid and elevated levels of interleukin-10 (IL-10) in the blood, which correlates with the vesicular



stage of the organism and cognitive impairment.<sup>26</sup> The number of lesions in the brain parenchyma is associated with cognitive impairment, but the location of the lesions does not show any correlation. Cognitive impairment can affect various domains, including attention, working memory, verbal abilities, planning, verbal learning processes, visual memory, and constructional abilities.<sup>26</sup>

Severe cognitive impairment can manifest as dementia. However, unlike typical dementia, some cases of neurocysticercosis-associated dementia can improve. Additionally, dementia in neurocysticercosis can occur across various age ranges and is not limited to the elderly. It's important to note that when encountering patients with progressive dementia, seizures, and hydrocephalus, especially in endemic areas, neurocysticercosis should be considered in the differential diagnosis.<sup>27</sup> Another study also indicates that seizure relapses can significantly impact cognitive function (66-87,5%), leading to dementia (12,5-16%) and a lower Intelligence Quotient (IQ < 70). Moreover, abnormal behavior, including anxiety and depression, was reported in 65.8% of cases. Patients with neurocysticercosis and epilepsy exhibited lower domain-specific cognitive functions, such as visual perception, immediate recall, analysis synthesis and reasoning, verbal ability, and memory, compared to both epilepsy patients and healthy controls. These cognitive disturbances are attributed to a combination of factors, including the direct effects of lesions, disruption of frontal-parietal-temporal networks, the effects of epilepsy and antiepileptic or antiparasitic treatment, and the production of inflammatory cytokines by the host immune response.<sup>17</sup>

### ***Treatment for Neurocysticercosis Patients***

The treatment of neurocysticercosis consists of several modalities depending on the characteristics of cyst stadium and part of brain involvement. Therapeutic might include symptomatic therapy, antiparasitic treatment, surgery (such as lesion resection or shunt placement in cases of hydrocephalus), or a combination of these modalities.<sup>28</sup> Most patients with neurocysticercosis and epilepsy respond well to first-line anti-epileptic treatment, and remission can be achieved with a single anti-epileptic drug (AED).<sup>2</sup> Carbamazepine is the most used AED, mainly because of its availability in endemic areas.<sup>28</sup> But nowadays, levetiracetam is also used in many places.<sup>29</sup> Monotherapy with phenytoin is also a common choice for dealing with seizures in neurocysticercosis patients.<sup>30</sup> Patients with calcified forms of neurocysticercosis represent true epilepsy and should receive the anti-epileptic drug for at least 2 years after the last seizure, followed by gradual withdrawal. However, even with this treatment, there remains a quite high risk of seizure recurrence.<sup>31</sup>

Patients with degenerating parasites that resolve without calcification can be interpreted as symptomatic seizures, allowing them to receive anti-epileptic therapy for a shorter period.<sup>28</sup> The discontinuation of oral AED can be considered in 85% of cases following the resolution of granulomas observed in imaging studies. However, it is not recommended to withdraw medication in patients with multiple cysts due to the heightened incidence of seizure relapses. In addition to antiepileptic drugs (AEDs), patients diagnosed with neurocysticercosis typically undergo antiparasitic treatment aimed at eliminating the causative parasites. However, it is important to note that these medications may simultaneously trigger inflammation and worsen various symptoms, including seizures. These antiparasitic drugs have the potential to eliminate up to 60-80% of the cysts. The drug of choice (DOC) for antiparasitic treatment is Albendazole, considering its superior efficacy, minimal side effects, enhanced penetration into the subarachnoid space, and cost-effectiveness.<sup>28</sup> The recommended dosage for Albendazole is 15 mg/kg per day for 8-15 days.

However, it is noteworthy that Albendazole may not be readily available in many countries. In such cases, Praziquantel can serve as an alternative, with a suggested dosage of 50 mg/kg per day for 15-30 days.<sup>32</sup> Combining these two regimens can enhance cysticidal efficacy.<sup>33</sup>

To avoid the potential side effects of antiparasitic treatment, particularly those that may adversely affect brain tissue, steroids are commonly administered concurrently to patients. The bioavailability of Albendazole and Praziquantel improves when steroids are included in the treatment regimen. Prednisone is the steroid most frequently used steroid for this condition, typically prescribed at a dosage of 1 mg/kg per day. Alternatively, Dexamethasone may also be given at a dosage ranging from 12 to 24 mg per day, with a maximum daily dose of 30 mg. Both steroids are typically initiated one day prior to the beginning of antiparasitic treatment, either administered intravenously or orally.<sup>32</sup> Steroid therapy is maintained for a duration of two weeks, followed by a gradual tapering off. Despite parasite resolution and the extensive use of antiparasitic regimens, some patients may continue to experience seizure relapses and epilepsy. This occurrence is primarily attributed to perilesional gliosis and recurrent inflammation. Consequently, long-term administration of AED is recommended for such cases.<sup>34</sup>

A study from Andrade et al. in 2010 which compares patients with neurocysticercosis, and healthy control and cryptogenic epilepsy showed that those with neurocysticercosis had worse executive function, verbal memory, constructional praxis, and verbal fluency. Dementia was found in 12,5% of patients with neurocysticercosis, and they found no correlation between seizure frequency and antiepileptic drug use.<sup>35</sup> This research proved that antiepileptic drugs were only useful to prevent the relapse of seizures, but they could not prevent the occurrence of cognitive impairment and dementia.

## CONCLUSION

Neurocysticercosis is one of the infectious diseases that can damage the central nervous system and lead to recurring seizures. Repeated and continuous seizures can result in brain tissue damage, causing irreversible decline in brain function. The main findings from the six discussed articles indicate that in patients with neurocysticercosis, there is indeed brain tissue damage leading to a decrease in cognitive function, particularly in aspects of conceptual understanding, verbal ability, as well as memory and spatial abilities. However, no differences in cognitive function decline were found between pediatric and adult patients. Additionally, neurocysticercosis patients may experience anatomical changes, such as hippocampal atrophy, which can also impact the cognitive abilities of the patients.

## REFERENCES

1. Carod JF, Dorny P. Cysticercosis in Madagascar. *The Journal of Infection in Developing Countries*. 2020 Sep 30;14(09):931–42.
2. Singhi P, Saini AG. Pediatric Neurocysticercosis. *The Indian Journal of Pediatrics*. 2019 Jan 20;86(1):76–82.
3. Garcia HH, Gonzalez AE, Gilman RH. *Taenia solium* Cysticercosis and Its Impact in Neurological Disease. *Clin Microbiol Rev*. 2020 Jun 17;33(3).
4. de Oliveira RS, Viana DC, Colli BO, Rajshekhar V, Salomão JFM. Pediatric neurocysticercosis. *Child's Nervous System*. 2018 Oct 9;34(10):1957–65.

5. Garcia HH. Neurocysticercosis. *Neurol Clin.* 2018 Nov;36(4):851–64.
6. Gripper LB, Welburn SC. Neurocysticercosis infection and disease—A review. *Acta Trop.* 2017 Feb;166:218–24.
7. Singhi P, Suthar R. Neurocysticercosis. *The Indian Journal of Pediatrics.* 2015 Feb 10;82(2):166–71.
8. Garcia HH, Nash TE, Del Brutto OH. Clinical symptoms, diagnosis, and treatment of neurocysticercosis. *Lancet Neurol.* 2014 Dec;13(12):1202–15.
9. Gupta MM, Chaudhary N, Pathak S, Agrawal N, Yadav J, Shrestha S, et al. Neurocysticercosis in Children with Seizures: A Cross-Sectional Study. *Int J Pediatr.* 2018;2018:1–6.
10. Rajshekhar V. Evolution of concepts in the management of cysticercosis of the brain: Then (1970) and now (2018). *Neurol India.* 2018;66(4):919.
11. Debacq G, Moyano LM, Garcia HH, Boumediene F, Marin B, Ngoungou EB, et al. Systematic review and meta-analysis estimating association of cysticercosis and neurocysticercosis with epilepsy. *PLoS Negl Trop Dis.* 2017 Mar 7;11(3):e0005153.
12. Singhi P, Malhi P, Suthar R, Deo B, Khandelwal NK. Long-term Cognitive Outcome of Children With Parenchymal Neurocysticercosis: A Prospective Observation Study. *J Child Neurol.* 2018 Jun 24;33(7):468–73.
13. Prasad R, Shambhavi, Mishra OP, Upadhyay SK, Singh TB, Singh UK. Cognitive and Behaviour Dysfunction of Children with Neurocysticercosis: A Cross-Sectional Study. *J Trop Pediatr.* 2014 Oct 1;60(5):358–62.
14. Verma A, Chopra B, Shankar Kaushik J, Gathwala G. Cognitive and behavioral profile of treatment-naïve children aged 6–14 years with neurocysticercosis from North India. *Ann Indian Acad Neurol.* 2018;21(4):300.
15. Del Brutto OH, Mera RM, Zambrano M, Costa AF, Román GC. The Association between Calcified Neurocysticercosis and Cognitive Performance: A Case–Control Study Nested to a Population-Based Cohort. *Am J Trop Med Hyg.* 2019 Feb 6;100(2):323–6.
16. Nau AL, Mwape KE, Wiefek J, Schmidt K, Abatih E, Dorny P, et al. Cognitive impairment and quality of life of people with epilepsy and neurocysticercosis in Zambia. *Epilepsy & Behavior.* 2018 Mar;80:354–9.
17. Johnson N, Saini AG, Malhi P, Khandelwal N, Singhi P. Comparison of Long-Term Outcomes Between 7 Days and 28 Days Albendazole Monotherapy in the Treatment of Single-Lesion Neurocysticercosis in Children. *J Child Neurol.* 2022 Jan 12;37(1):28–34.
18. Falco-Walter JJ, Scheffer IE, Fisher RS. The new definition and classification of seizures and epilepsy. *Epilepsy Res.* 2018 Jan;139:73–9.
19. Venkat B, Aggarwal N, Makhaik S, Sood R. A comprehensive review of imaging findings in human cysticercosis. *Jpn J Radiol.* 2016 Apr 23;34(4):241–57.
20. Del Brutto OH, Nash TE, White AC, Rajshekhar V, Wilkins PP, Singh G, et al. Revised diagnostic criteria for neurocysticercosis. *J Neurol Sci.* 2017 Jan;372:202–10.
21. Del Brutto OH. Human Neurocysticercosis: An Overview. *Pathogens.* 2022 Oct 20;11(10):1212.
22. Ratcliffe C, Adan G, Marson A, Solomon T, Saini J, Sinha S, et al. Neurocysticercosis-related seizures: Imaging biomarkers. *Seizure: European Journal of Epilepsy.* 2023 May;108:13–23.
23. Singhi P, GAHLOT A. Pediatric neurocysticercosis: current challenges and future prospects. *Pediatric Health Med Ther.* 2016 Mar;5.

24. Nau AL, Mwape KE, Wiefek J, Schmidt K, Abatih E, Dorny P, et al. Cognitive impairment and quality of life of people with epilepsy and neurocysticercosis in Zambia. *Epilepsy & Behavior*. 2018 Mar;80:354–9.
25. Johnson N, Saini AG, Malhi P, Khandelwal N, Singhi P. Comparison of Long-Term Outcomes Between 7 Days and 28 Days Albendazole Monotherapy in the Treatment of Single-Lesion Neurocysticercosis in Children. *J Child Neurol*. 2022 Jan 12;37(1):28–34.
26. Varghese V, Chandra SR, Christopher R, Rajeswaran J, Prasad C, Subasree R, et al. Cognitive Dysfunction and its Determinants in Patients with Neurocysticercosis. *Indian J Psychol Med*. 2016 Mar 1;38(2):142–6.
27. Wiwanitkit V. Dementia and neurocysticercosis. *Acta Neurol Taiwan*. 2014;23(1):1–3.
28. Bustos J, Gonzales I, Saavedra H, Handali S, Garcia HH. Neurocysticercosis. A frequent cause of seizures, epilepsy, and other neurological morbidity in most of the world. *J Neurol Sci*. 2021 Aug;427:117527.
29. Santhosh AP, Kumar Goyal M, Modi M, Kharbanda PS, Ahuja CK, Tandyala N, et al. Carbamazepine versus levetiracetam in epilepsy due to neurocysticercosis. *Acta Neurol Scand*. 2021 Mar 22;143(3):242–7.
30. Frackowiak M, Sharma M, Singh T, Mathew A, Michael BD. Antiepileptic drugs for seizure control in people with neurocysticercosis. *Cochrane Database of Systematic Reviews*. 2019 Oct 14;
31. Burneo JG, Cavazos JE. Neurocysticercosis and Epilepsy. *Epilepsy Curr*. 2014 Jan 1;14(2\_suppl):23–8.
32. Winkler AS, Willingham AL, Sikasunge CS, Schmutzhard E. Epilepsy and neurocysticercosis in sub-Saharan Africa. *Wien Klin Wochenschr*. 2009 Oct 1;121(S3):3–12.
33. Garcia HH, Gonzalez AE, Gilman RH. *Taenia solium* cysticercosis and its impact in neurological disease. *Clin Microbiol Rev*. 2020;33(3):10–1128.
34. Carpio A, Fleury A, Romo ML, Abraham R. Neurocysticercosis: the good, the bad, and the missing. *Expert Rev Neurother*. 2018 Apr 3;18(4):289–301.
35. Ciampi de Andrade D, Rodrigues CL, Abraham R, Castro LHM, Livramento JA, Machado LR, et al. Cognitive impairment and dementia in neurocysticercosis. *Neurology*. 2010 Apr 20;74(16):1288–95.