

Extra Cranial Facial Nerve Anatomical Dissection: Fresh Tissue Vs Embalmed Tissue

¹Fifi Veronica*, ²Rani Seprina, ¹Nandina Oktavina, ³Nita Novita
¹Department of Biomedical Sciences, Faculty of Medicine Universitas Padjadjaran
²Department of Plastic Surgery, Hasan Sadikin Hospital Bandung
³Department of Forensic and Medicolegal, Hasan Sadikin Hospital Bandung
email: fifi@unpad.ac.id

received 15 Feb; accepted 17 Apr 2022

Abstrak

Pengetahuan dasar topografi anatomi dari nervus fasialis sangat penting untuk pada aplikasi klinis. Ukuran nervus fasialis yang sangat kecil dan kurangnya penanda struktur saraf tersebut pada daerah wajah menjadikan cabang ekstra kranial dari nervus fasialis sulit untuk diidentifikasi. Untuk itu pentingnya kemampuan ketrampilan diseksi pada beberapa jaringan seperti jaringan yang segar dan jaringan yang sudah dilakukan preservasi. Tujuan penelitian ini adalah untuk membandingkan diseksi anatomi dari nervus fasialis preparat dari jaringan yang segar dan dari jaringan yang sudah dilakukan preservasi. Metode yang digunakan untuk menentukan topografi ekstra kranial nervus fasialis dilakukan dengan diseksi anatomi pada daerah kepala dari 3 jenazah yang berasal dari Departemen Forensik dan 3 kadaver laboratorium. Garis insisi dimulai dari garis tengah melewati glabella, menuju puncak hidung dan sampai pada lekukan vertikal antara hidung dan mulut. Kemudian dengan menyusuri bagian-bagian kulit, lapisan demi lapisan akan dipisahkan untuk mengidentifikasi cabang dari nervus fasialis. Hasil penelitian ini menunjukkan bahwa pada diseksi anatomi dengan menggunakan jaringan yang sudah dipreservasi, nervus fasialis dan cabang-cabangnya mudah untuk diidentifikasi, tetapi sulit untuk memisahkan lapisan-lapisan kulit daerah wajah dari lapisan Superficial Musculo Aponeurotic System (SMAS). Kesimpulan penelitian menunjukkan bahwa identifikasi ekstra kranial nervus fasialis lebih mudah dilakukan pada jaringan yang sudah terpreservasi. Sedangkan untuk mengidentifikasi lapisan lapisan kulit pada bagian wajah lebih mudah dilakukan pada jaringan yang masih segar.

Kata kunci : Ekstra kranial nervus fasialis, jaringan segar, kadaver

Abstract

Anatomical topography of the facial nerve is very important as one of the basic knowledge for clinical application. Extra cranial facial nerve branches were difficult to identify because of their smaller size and lack of consistent landmark. Dissection skill needs experience with various tissue, like fresh and embalmed tissue. This study was aimed to compare the facial nerve anatomical dissection by using fresh tissue and embalmed tissue cadaver. Three fresh tissue cadaver from Forensic Department and three embalmed tissue cadaver (after 2 months preserved by ethanol) from the Anatomy Department were used to anatomically dissect the topography of the extra cranial facial nerve. The incision line started from the midline across the glabella, tip of the nose until the philtral groove. The skin flap from the midline to the lateral until we find the branches of the facial nerve. The anatomical dissection of the extra cranial facial nerve from 3 embalmed tissue can provide the dissected facial nerve and its branches. But it is hardly difficult to separate the skin from the Superficial Musculo Aponeurotic System (SMAS) compared with fresh cadaveric tissue. Embalmed cadaver and fresh tissue from the post mortem body can be used for anatomical dissection study of the extra cranial facial nerve. Each different tissue has its own difficulties depending on the aim of the dissection study.

Keywords: Extra Cranial Facial Nerve, Fresh and Embalmed Cadaveric Tissue

1. Introduction

Facial nerve is a one of cranial nerve with longer pathway than another cranial nerve. It has intra and extra cranial (extra temporal) nerves.¹ Basic knowledge about topography facial nerve is very important, especially for clinician when they open face region, like parotidectomy, facial surgery and facial grafting. Facial nerve injury most commonly caused by variation branching itself.²

Identification of the facial nerve could be performed through study of textbooks, virtual, or through direct dissection on cadaver. Study through dissection on the cadaver has highest value to students' understanding process of anatomy structure and its topography. Dissection as a part of medical studies' curriculum, as in bachelor or speciality program, has a particular implication to support understanding of topography and dissection skill in the future.² Development of dissection activity in medicine studies, is never apart from the advancement of cadaver's preservation. Techniques of cadaver development with formalin has been known and used in Anatomy department in almost all medical faculties in Indonesia. Formalin's effect that is not environmentally friendly, caused many of new developments in preservation like plastination, *Thiel's method*, and other formulas which are being developed in each of medicine studies especially in Anatomy department. Department of Anatomy, Physiology and Cell Biology Universitas Padjadjaran has particular formula to cadaver preservation. This formula consist of mixture of formalin in small quantity, ethanol, glycerin and some other mixtures. The result of preservation with ethanol produces cadaver which is more flexible, moist and reduced smell of the formalin.³

Dissection of extra temporal facial nerve could be done through anatomy dissection or surgical dissection. Other than having a very small size, topography and variation of the branches, facial nerve has its own uniqueness. Approach of anatomy dissection from midline part of the face through the lateral part in

preauricular. The aim of this article is to pictures the topography and structure from extra temporal facial nerve through anatomy dissection on cadaver that has been preserved with ethanol compared with fresh cadaver that has not been preserved.^{4,5}

2. Material and Method

This study was approved and carried out by the guidelines of the Ethics Committee of Faculty Medicine Universitas Padjadjaran. This work was carried out at the Department of Biomedical Sciences and Department of Forensic and Medicolegal Hasan Sadikin Hospital. This study is a descriptive study with cadaver as a subject. Three face of cadaver samples (2 male and 1 female) that has been preserved with ethanol of minimum of 2 months, and 3 face of cadaver samples (2 male and 1 female) that has not been preserved (fresh) from department of forensic studies RSHS Bandung. Two groups of cadaver is dissected on the midline part of the face to the lateral. Facial nerve is observed with loop glasses.

Steps of anatomy dissection of facial nerve:

The heads were turned lateral side to expose preauricular region for dissection. Firstly, incision is performed on the midline of the face from the border of hairline through glabella, highest point of the nose, philtral groove through thyroidea cartilage. Secondly, a skin flap is made from midline to lateral, continue with subcutis flap and SMAS from midline to lateral, identify the stylomastoid foramen, superficial parotid gland, tragus cartilage, angulus mandibular and digastric muscle. Then continue the procedure with identification of the facial nerve's main trunk. The length of facial nerve from main trunk to the tragus, angulus mandible, main branching and canthus lateralis were determined. We use a compass with a centimeter scale to measure distance and length.

3. Result

Cadaver Preserved With Ethanol (Embalmed Cadaver)



Fig 1 . Step of anatomical dissection I: A line is drawn on midline, through glabella-highest point of the nose-phiral groove-thyroid gland



Fig 2. Step of anatomical dissection II : Incision continue from midline to lateral with separation of the layers, flapping from midline to lateral. Subcutis is separated from SMAS part from the lower part. Flapping is performed until the lateral.

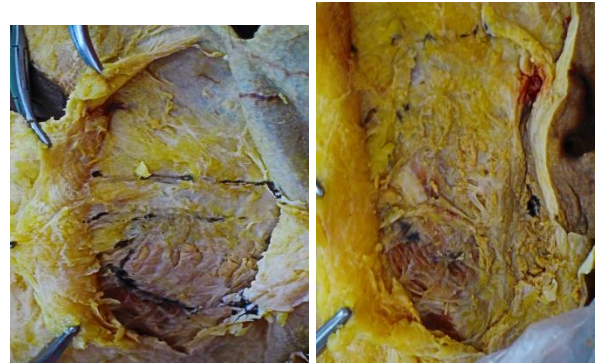


Fig. 3A

Fig. 3B

Fig. 3(A) and (B) are appearance condition of subcutaneous tissue from embalmed cadaver (different cadavers). Pointed arrow in Fig.3 (B) shows the trunk of facial nerve, which rigid and easily to identified. But layer of surrounded connective tissue (SMASH) difficult to separate.

Fig. 1 and 2 are steps anatomical dissection in embalmed cadaver. In dissection with embalmed cadaver that is treated with ethanol, after separate the subcutis layer, the SMAS layer on the lower part is difficult to separate, but the facial nerve main trunk and its branches can be identified between two of the fascias on parotid gland layers (**Fig. 3A and 3 B**). The structure of the facial nerve appears more rigid so that it is more stronger in structural, not vulnerable compares to the fresh cadaver. This is might be caused by the effect of ethanol preservation effect.

Fresh Tissue

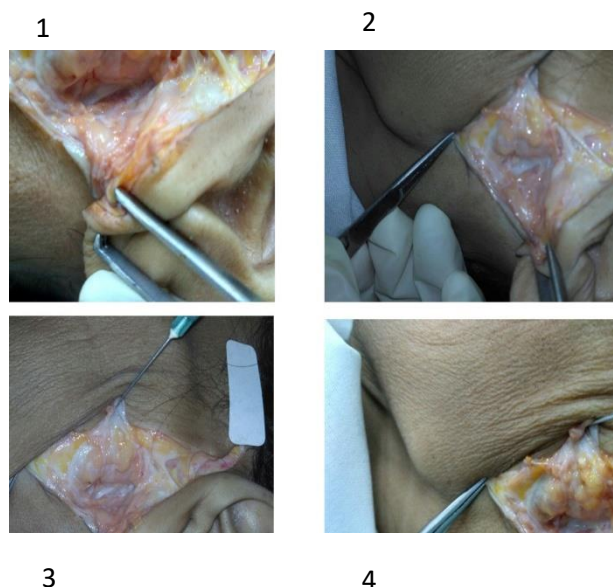


Fig. 4 Anatomical dissection with fresh cadaver . Picture no. 1 & 2 : shows Superficial Musculo Apponeurotic System (SMAS). Layer of SMAS can easily to separate because of the fresh condition of the connective tissue. Picture no. 3, 4 & point arrow, shows extra cranial facial nerve. The nerve hardly to identified, only by using loop. The nerve easily to rupture.

In a dissection with fresh tissue, separation of the layers can easily be performed (**Fig. 4**). The layer of subcutis with SMAS on the lower part is easy to be released. The structure of the facial nerve is difficult to preserve, especially the main trunk which is located between the fascia on parotid gland. Extra care is needed to the preservation process.

The measurement

The exit of facial nerve from the skull through the stylomastoid foramen without exception in both 6 face cadavers and fresh tissue. The mean distance of the facial nerve trunk to the tragus, angulus mandible, main branching and canthus lateralis describe in **table 1**. This study revealed no significant correlation length of facial nerve from main trunk to the item structure measured between dissection using embalmed cadaver with fresh tissue from post mortem body.

Table 1. Comparison length of extra facial nerve dissection in embalmed cadaver and fresh tissue*

	Length of Extra cranial facial nerve From Stylomastoid foramen to			
	Tragus	Angulus mandible	Main branch	Canthus lateralis
Embalmed cadaver	22,3±1,52	37±6,08	5,6±0,57	101,66±1,52
Fresh tissue	21,3±2,30	30,33±0,57	5,33±0,57	106±6,55

4. Discussion

The trunk of facial nerve between stylomastoid foramen and its bifurcation is frequently dissected during surgery. Segment or part of Facial nerve which located in complex area anatomy must be clearly understood to prevent iatrogenic damage of facial nerve. Injury of facial nerve can cause palsy.

Identification of facial nerve trunk is hardly difficult because it's surrounded dense connective tissue. The knowledge of dimension facial nerve are important for surgical procedure. Different condition tissue influence the structure of the nerve and surrounded connective tissue .

Embalmed cadavers are the primary tools for teaching anatomy. But changed color and texture of structure organs and hardening of connective tissue encountered difficulties of anatomical study and their perception of the nerve. Fresh cadaver and embalmed cadaver each has its own advantages and disadvantages. Fresh cadaver gives facial nerve's topography include layers of face's regio. On the other hand, embalmed cadaver, structure of the face is more difficult to layer separation, but the nerve structure appears more rigid, not

vulnerable. So that for the students that needs skill advancement and understanding to facial nerve's anatomy topography structure of an anatomy dissection in fresh as well as in embalmed cadaver has its own advantages.

5. Conclusion:

Embalmed cadaver and fresh tissue from post mortem body can be used for anatomical dissection study of extra cranial facial nerve. Each different tissue has its own difficulties depends the aim of the dissection study. More studies about variation facial nerve topography in Indonesian people can be done by using combination of this method.

ACKNOWLEDGEMENTS

This research were funded by Universitas Padjadjaran Internal Grant, number 2477 /UN6.C/PM/2018

CONFLICT OF INTEREST

The authors declare that they have no conflicts of interest with the contents of this article.

References

1. Williams,PL 1995, Banister, LH & Berry,MM 1995, Gray's Anatomy, 38th ed, New York Churchill-Livingstone.
2. Watanabe, K, Shoja,M & Loukas, M 2016, Anatomy for Plastic Surgery of the Face, Head, Thieme.
3. Anatomy, Physiology and Cell Biology Department, Protocols of Cadaveric Formulation, Medicine Faculty, Unpad, Bandung
4. Potgieter,W,Meiring,JH & Boon,JM 2005, 'Mandibular landmark as an aid in minimizing injury to the marginal branc: A metric and geometrical study', Clin Anat, vol.18, hh.171-178.
5. Ishikawa,Y 1990, 'Anatomical Study on the Distribution of the Temporal branch of the Facial Nerve ', J Craniomaxillofac Surg, vol. 18, hh.287-292.
6. Park, IY, Lee, ME 1977, 'A Morphological Study of the Parotid Gland and the Peripheral Branches of The facial Nerve in Korean', Yonsei MedJ, vol. 18, hh.45-51.
7. Katz, AD, Catalano, P 1987, 'The Clinical Significance of the Various Anastomosis Branches of the Facial Nerve : Report of 100 patients' , Arch Otolaryngol Head and Neck Surg.vol. 113, hh. 959-962.

